

# Treatment of high congenital dislocated hips by gradual distraction with an Ilizarov fixator, followed by cementless total hip arthroplasty

Ahmed E. Rady, El-Hussein M. El-Moatassem and Mootaz F. Thakeb

Department of Orthopedic, Faculty of Medicine,  
Ain Shams University, Cairo, Egypt

Correspondence to El-Hussein M. El-Moatassem, MD,  
Department of Orthopedic, Faculty of Medicine,  
Ain Shams University, Cairo, Egypt  
Tel: +20 1 005 806086;  
e-mail: hmoatassem@yahoo.com

Received 1 April 2011

Accepted 26 April 2011

Egyptian Orthopedic Journal 2012, 47:361–367

## Background

The treatment of complete congenital dislocation of the hip with total hip arthroplasty (THA) in adults is a challenging surgical procedure. The successful placement of the acetabular component demands an anatomic reduction without causing excessive compressive loads across the hip joint. To accomplish this, several maneuvers have been introduced. Bone grafting, cotyloplasty, or a high hip center have been proposed. In this study, the authors report a combination of slow continuous iliofemoral distraction in patients requiring a distraction distance over 40 mm, followed by a soft-tissue release and cementless THA.

## Patients and methods

Between 2004 and 2010, 12 adult patients (eight women, four men), 12 hips, with high congenital dislocation hip (Crowe type IV) were studied. All patients had constant pain despite nonoperative treatment, consisting of activity modification, physical therapy, and the use of nonsteroidal anti-inflammatory drugs. All patients had a limping gait because of limb-length discrepancy before the surgery that averaged 5.5 cm (range 4.5–7.0 cm). We used an Ilizarov fixator with iliofemoral distraction to treat high congenital dislocation of the hips before performing cementless THA. The patients ranged in age from 19 to 48 years (average 32.4 years). At an average follow-up period of 3.3 years (average 2–5.5 years), clinical and radiological data were collected. No patient was lost to follow-up. An average distraction distance of 5.5 cm (range 4.5–7.0 cm) was performed over 31.5 days (range 26–40 days). Clinical data were collected including the Harris hip score. All patients underwent THA on the day the external fixator was removed.

## Results

All the patients had undergone an average effective iliofemoral distraction of 1.7 mm/day (1.5–1.8 mm/day), monitored clinically, although the distraction of the external fixator was much higher. The distraction period ranged from 26 to 40 days.

The limb-length inequality at the time of the latest follow-up ranged from 0 to 2.0 cm (average 0.5 cm). There was no overlengthening on the side of the index surgery.

All patients underwent THA on the day the external fixator was removed. The mean Harris hip score improved from an average 42.5 points preoperatively (range 28–60 points) to an average 89 points (range 76–98 points) at the time of the latest follow-up.

## Conclusion

This study shows that a closed technique utilizing an Ilizarov fixator for iliofemoral distraction, followed by cementless THA might be a good alternative compared with shortening osteotomies in one-stage THA for patients with a high congenital hip dislocation over 40 mm.

## Keywords:

high congenital dislocated hips, Ilizarov gradual distraction, total hip arthroplasty

Egypt Orthop J 47:361–367  
© 2012 The Egyptian Orthopaedic Association  
1110-1148

## Introduction

The treatment of complete congenital dislocation of the hip with total hip arthroplasty (THA) in adults is a challenging surgical procedure. Complications and failures are more common with this approach than with a routine hip arthroplasty [1–6]. The distorted anatomy in

a congenital dislocation of the hip may include abnormal neurovascular structures, soft-tissue contractures, abnormal location of the hip center, leg-length discrepancy, and increased anteversion of the femoral neck angle [7]. The successful placement of the acetabular component demands an anatomic reduction without causing excessive compressive loads across the hip joint [8]. To accomplish

this, several maneuvers have been introduced; bone grafting, cotyloplasty [9,10], or a high hip center [11–13] have been proposed. In the femur, rotational and shortening osteotomies, followed by cemented and cementless stems have been applied [14]. Reduction of the dislocation, one-step soft-tissue releases, or shortening osteotomies of the femur have been described [10,14,15]. However, when a high dislocation (Crowe type IV) is present, soft-tissue contractures and concerns of sciatic nerve stretching make it difficult to reduce the prosthetic femoral head into the acetabular component in the anatomical position. The exact amount of distraction that will cause sciatic nerve dysfunction is not known, but acute lengthening of more than 2–4 cm has been associated with an increased risk of nerve injury [2]. In this study, the authors report a combination of a slow continuous iliofemoral distraction in patients requiring a distraction distance over 40 mm, followed by a soft-tissue release and cementless THA.

### Patients and methods

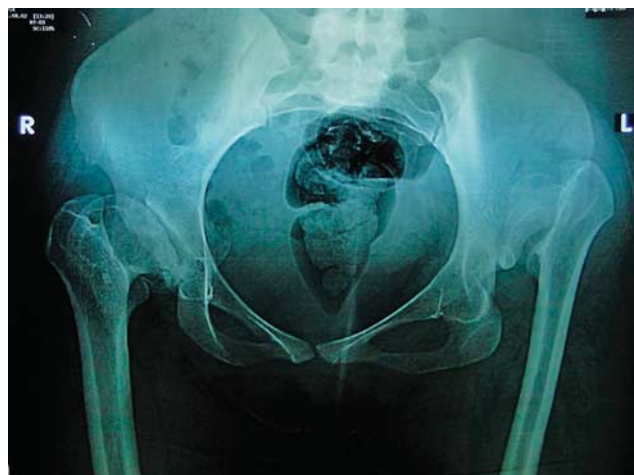Between 2004 and 2010, 12 adult patients (eight women, four men), 12 hips, with a high congenital dislocation hip (CDH) (Crowe type IV) [16] and proximal displacement of the femur above 40 mm were treated with iliofemoral distraction, followed by cementless THA. All patients had constant pain despite nonoperative treatment, consisting of activity modification, physical therapy, and the use of nonsteroidal anti-inflammatory drugs. Three patients had undergone pelvic osteotomies surgery before our procedure. This study was approved by our institutional committee for clinical research and informed consent was obtained from the patients included in the study. The patients' ranged in age from 19 to 48 years (average 32.4 years). At an average follow-up period of 3.3 years (2–5.5 years), clinical and radiological data were collected. All the patients had unilateral congenital dislocation of the hips, except two patients (cases 1 and 6) with the contralateral hips, who were not included in the study as the other hips did not require iliofemoral distraction. No patient was lost to follow-up.

An average distraction distance of 5.5 cm (range 4.5–7.0 cm) was performed over 31.5 days (range 26–40 days). Clinical data were collected including the Harris hip score. Radiologically, anteroposterior and lateral radiographs of the femur were obtained (Fig. 1). Templates were used to estimate the size of the prosthetic components. We used a three-dimensional computed tomography scan to assess the native hip socket suitability for augmentation with structural bone graft and/or medialization of the cup (Fig. 2). The goal was to equalize the limb lengths. We attempted to place the acetabular component in the anatomical position in all the patients (Table 1).

#### First-step iliofemoral distraction

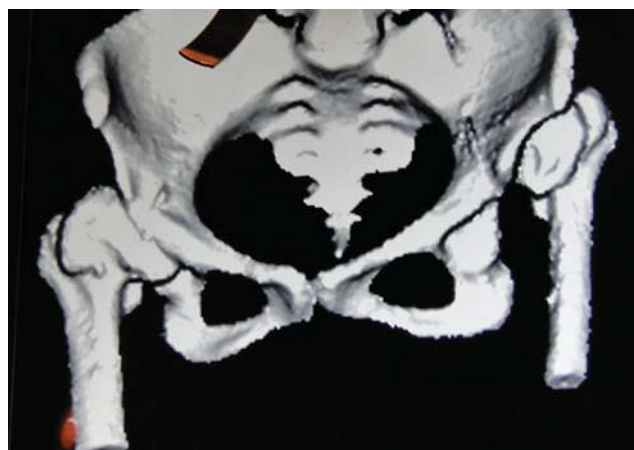The patient was placed supine on a radiolucent table following previous antibiotic administration. We used an

**Figure 1**



Case no. 1: A 19-year-old woman with a Crowe type IV high dislocation of the right hip had a preoperative limb-length discrepancy of 6 cm.

**Figure 2**



Three dimensional computed tomography scan showing shallow true acetabulum.

Ilizarov fixator; one arch of 120° was mounted on the pelvis with the application of three to four hydroxyapatite 5 mm Schanz screws and two supra-acetabular half pins were placed under X-ray control (Fig. 3a–d). Two additional half pins were inserted between the medial and the lateral walls of the ilium. These pins together comprised the proximal montage; we spread our fixation pins between the ilium and the supra-acetabular area to achieve maximum area of fixation, although the bone density is much higher in the supra-acetabular area, which provides greater pillar of fixation. Another complete Ilizarov ring of 180–200 mm in size was mounted in the distal femur fixed with a bionet Ilizarov wire and two to three Schanz screws. The arch and the Ilizarov ring were connected by oblique supports and connecting rods. The patients were allowed to ambulate on crutches with toe-touch weight bearing. All patients received a prophylactic dose of low-molecular-weight heparin and

**Table 1 Patient demographics and outcome measures**

Cases	Age (years)/sex/side	Limb-length discrepancy(cm)		Pelvicostectomy	Follow-up (years)	Complications	Harris hip score	
		Preoperative	Latest				Preoperative	Most recent
1	19/F/L	6	0	SO	2	Medial wall perforation	35	88
2	35/M/L	5	0		2.5		52	96
3	33/M/L	6	0		2		38	90
4	27/M/R	6	1	SO	3		46	86
5	25/F/R	6	1	SO	3	Revision of cup	28	76
6	38/F/R	7	2		4	Loose pins	42	87
7	29/M/L	4.5	0		2.5		36	94
8	48/F/L	5.5	0		4		44	92
9	24/F/L	5	0		3.5		35	89
10	40/F/L	6	1		5	Loose pins	45	86
11	34/F/L	5	1		3		50	86
12	37/F/L	4.5	0		5.5		60	98

F, female; L, left; M, male; R, right; SO, Salter osteotomy.

leg stockings for thromboprophylaxis. Routinely, we administered intravenous antibiotics for 5 days for infection prophylaxis and then an oral antibiotic until the removal of the fixator. Iliofemoral distraction was performed at a distraction of 2 mm each day starting on the second postoperative day, as indicated on the calibrated fixation rods, and the effective length was revised every 2 weeks clinically. The patients were clearly instructed on how to carry out the distraction (0.5 mm/6 h) and on pin-site care. The effective speed measured clinically was not the distance displayed on the distraction apparatus. Fortunately, we did not encounter any complication of either sciatic nerve traction palsy or limb vascularity.

The patients were discharged 1–2 days after surgery. At home, they distracted independently, and were regularly monitored in the authors' outpatient clinic.

### Second-step surgical procedure

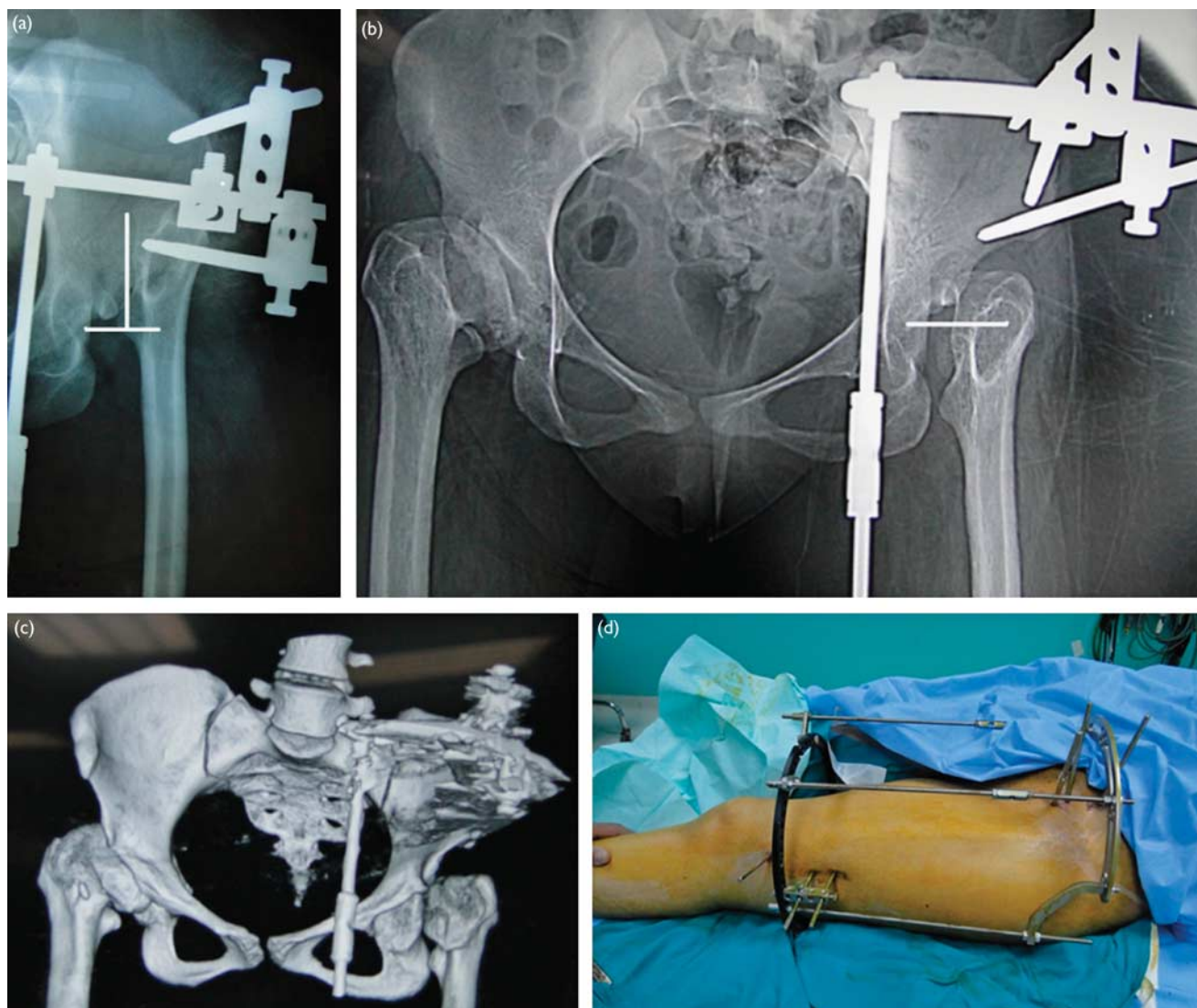
The iliofemoral distraction was continued until the femoral head was approximately at the center of the cup before the second surgery. This eased the reduction in most cases. Again, all procedures were carried out in the lateral position after the Ilizarov fixator was demounted, the Steinmann screws and Ilizarov wire were removed, and the pin tracks were debrided with saline impregnated with gentamicin solution. We used Rady's approach, which is a modification of the Hardinge exposure. The approach is used with the patients in a lateral position. A gently curved skin incision was made starting from a point half-way between the posterior superior iliac spine and of the greater trochanter, and then directed toward the tip of the greater trochanter, and then straight distally along the anterior aspect of the femoral shaft. The subcutaneous fat and iliotibial band were incised and opened along the same line of skin incision. The gluteus maximus muscle was split in the proximal part of the incision along the line of its fibers.

Vastus lateralis and gluteus medius muscle were exposed in the wound depth. The distal one-third of the gluteus medius muscle was incised between two stay sutures

and reflected medially, exposing the gluteus minimus underneath. A Hohmann retractor was placed beneath the medially reflected distal one-third of the gluteus medius muscle to demonstrate the gluteus minimus underneath. Gluteus minimus was again incised between two stay sutures and also reflected medially, exposing the anterior capsule underneath. Three Hohmann retractors were then placed; an angled one was placed with its tip over the anterior margin of the acetabulum retracting behind it the gluteus medius and minimus muscle, another blunt Hohmann was placed inferomedial to the hip capsule, and a third was placed superolateral to the hip capsule. The anterior hip capsule was widely exposed. Finally, anterior capsulectomy was performed exposing the femoral head and the entire hip joint. The femur was adducted and externally rotated so that it could be easily dislocated anteriorly.

Further exposure of the acetabulum superiorly, anteriorly, and posteriorly could be gained by elevating soft tissues from the ilium and inserting curved Hoffman retractors underneath, without the risk of injuring the superior gluteal nerve or even subjecting it to traction injury [17]. The joint capsule was excised as completely as possible. The soft tissue and any bone overgrowth obstructing the true acetabulum were removed. The anterior and posterior borders of the innominate bone were identified to assess the three-dimensional structure of the bone stock. The location of the best bone stock in which to place the prosthetic cup was marked. The acetabulum was prepared with osteotomes to accommodate the smallest reamer (38 mm). It was then enlarged and deepened to the largest possible size without breaching the anterior or the posterior border of the innominate bone. In hips with a very shallow acetabulum, the medial wall of the acetabulum was reamed carefully. However, the medial wall of the acetabulum was inadvertently perforated in two cases. The acetabular cup was implanted using a press-fit technique in only one case. Additional screws were used to fix the cup in 11 hips. The excised femoral head was used as a structural bone graft to augment the acetabulum in two patients with less than 70% coverage

Figure 3



Case no. 1: (a) Radiograph showing iliofemoral distraction. (b) The left femur was pulled 6 cm. (c) Computed tomography scan showing completed iliofemoral distraction. (d) Clinical photo showing the application of an Iliarov fixator for iliofemoral distraction.

of the cup by native bone (Fig. 4a–d). The femoral canal was reamed with the guide of the trancondylar axis for orientation. In all patients, a standard hydroxyapatite-coated cementless stem (Coral ATM Stem, Depuy International) and an acetabular cup (Pinnacle Multihole Cup, Depuy International), Biolox Delta Ceramax, metal insert, femoral stem size 8 and ceramic head size 28, were used.

#### Postoperative care

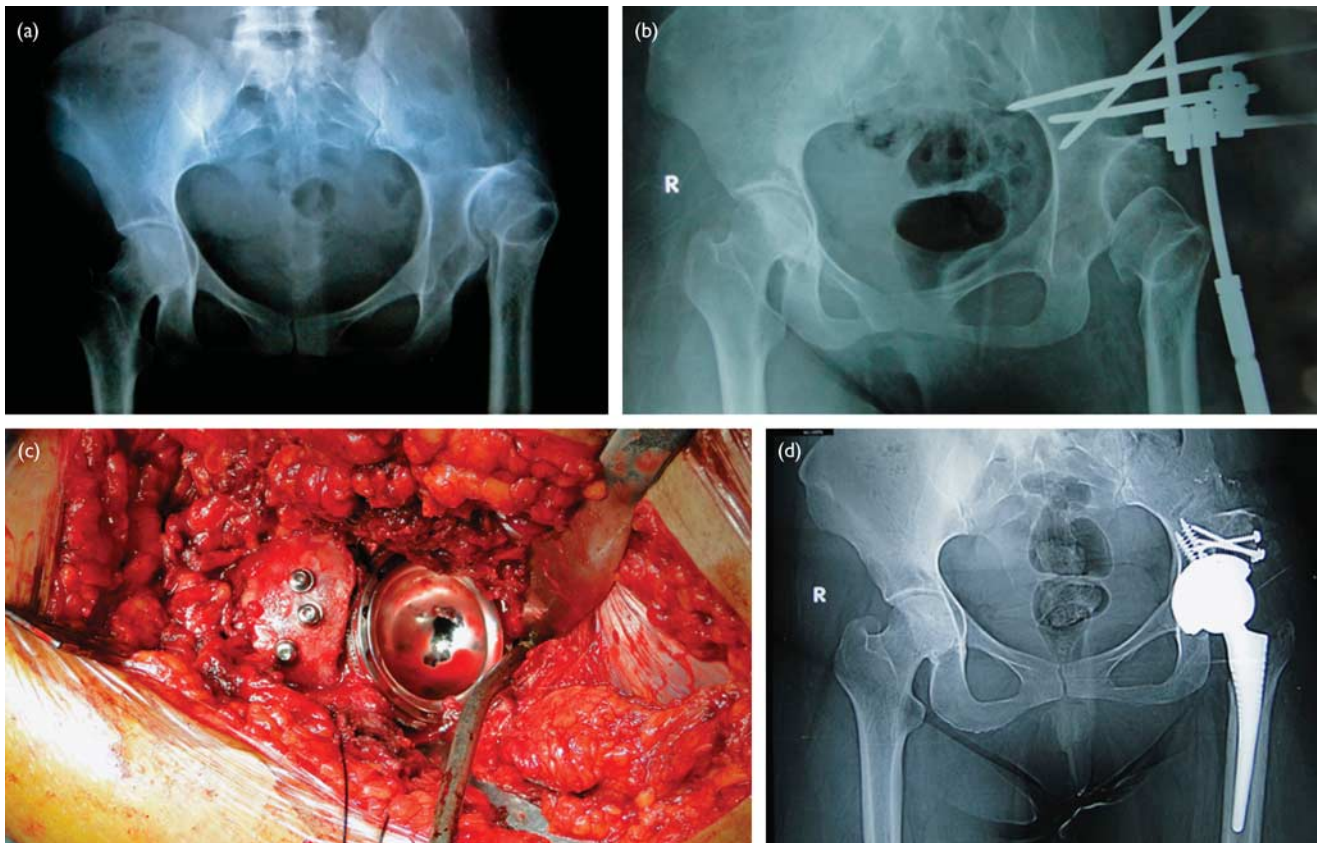
Muscle-strengthening exercises and walking with crutches were started 3 days after the surgery. Full weight bearing was allowed and gait training was initiated at 6 weeks after the surgery when the patient had not required a bone graft and 12 weeks when the patient had received a structural bone graft.

#### Results

The limb-length discrepancy before the surgery averaged 5.5 cm (range 4.5–7.0 cm). The distraction period ranged from 26 to 40 days. An average effective iliofemoral distraction of 1.7 mm/day (range 1.5–1.8 mm/day) was monitored clinically, although the distraction of the external fixator was much higher. The limb-length inequality at the time of the latest follow-up ranged from 0 to 2.0 cm (average 0.5 cm). There was no overlengthening on the side of the index surgery. All patients showed absence of periprosthetic radiolucencies and component migration. In one patient, the acetabular cup was loose and required revision. There were no pin-track infections. However, the iliac pins loosened in two patients and were removed in the outpatient clinic and fixation was secured by the supra-acetabular pins. All patients underwent THA on the day the external



Figure 4



Case no. 9: (a) Twenty-four-year-old woman with a Crowe type IV high dislocation of the left hip with a preoperative limb-length discrepancy of 5 cm. (b) Application of an Ilizarov fixator during iliofemoral distraction. (c) Intraoperative photo showing complete coverage of the cup after the application of a bone graft fixed by three cancellous screws. (d) Cementless total hip prosthesis was implanted and the roof was reinforced with an autogenous bone graft from the excised femoral head.

fixator was removed. None of the femoral pins loosened. The diameter of the cup was 42 mm in five patients, 44 mm in three patients, 46 mm in two patients, and 48 mm in two patients. All of the femoral heads were ceramic and 28 mm in diameter. All the femoral stems were size 8. The operative time for THA averaged 135 min (range 120–160 min). The mean estimated blood loss (including postoperative drainage) was 750 ml (range 600–1000 ml). The mean Harris hip score improved from average 42.5 points preoperatively (range 28–60 points) to 89 points (range 76–98 points) at the time of the latest follow-up. No patient required crutches or a cane for walking and none required a shoe-lift. There were no dislocations of the total hip prosthesis and no superficial or deep infections.

## Discussion

The replacement of severely dysplastic and completely dislocated hips is a major orthopedic problem. The patients tend to be younger, which places them at an increased risk for mechanical failure of the implant fixation [18,19]. Charnley and Feagin [1] believed that THA may be acceptable for patients with congenital subluxation, but not for patients with congenital disloca-

tion of the hip if more than 5 mm at the lateral edge of the smallest available component is unsupported by bone. Coventry [20] also believed that THA is contraindicated in patients whose acetabular bone stock is deficient. Others preferred to place the cup in a false acetabulum [21]. Acetabular components placed high on the pelvic wall have been shown to loosen [22], and the Trendelenburg gait persisted in these patients [22–24]. The severe limb-length inequality results in a marked limp. Furthermore, the uneven knee height cannot be corrected even with a large shoe-lift; restoration of the normal hip center would be ideal in these patients, but it is technically difficult.

Placement of the acetabular component in the original location has been advocated by many authors [4,22–25]. Restoration of the normal hip center would be ideal in these patients, but it is technically difficult. Recent clinical studies have shown excellent results when good primary stability was achieved and the hip joint center had been restored properly [26]. Normal acetabular position would allow maximum coverage for the cup, without causing excessive compressive loads across the hip joint or the need for extensive structural bone grafting. Bone grafting may sometimes be required to reinforce the bone above the acetabular component if the iliac bone was severely hypoplastic [11,27]. The rate of

nerve palsy is high after THA in patients with hip dysplasia, and this has been commonly attributed to stretching of the nerves during lengthening [28]. There were no clinically evident femoral or sciatic nerve palsies in our series with the use of gradual iliofemoral distraction.

Major obstacles are associated with restoration of the anatomic hip center, and anatomical placement of the acetabular cup in the area of the true acetabulum is well known [8,10,29]. Early experiences of THA in patients with high CDH were thus discouraging [1]. Only a few long-term results of THA in CDH have been published: a 78% survival rate at 20 years was reported for both cemented Charnley stems and cemented cups without or with reinforcement rings [30]. Similarly, a 93% survival rate at 10 and 75% at 15 years was reported for hybrid THA using noncemented cups and cemented stems [29]. The latter study showed higher late success rates for THA in less severe dysplastic cases. These results cannot be compared with our results as we reported preliminary results and our follow-up was short term (3.5 years).

The standard technique used to reduce the hip has been femoral shortening, through either a midtrochanteric or, more often, a subtrochanteric resection osteotomy. This technique might be advantageous because only one surgery has to be performed, no external fixation device is mounted, and the treatment period is shorter compared with the technique described in the present study. Shortening osteotomies, however, mainly address pain relief. The problems of leg-length discrepancy and limp are hardly solved with the use of this technique. The technique of preoperative iliofemoral distraction that we described allows hip reduction without sacrificing femoral length. It further stretches the surrounding soft tissues, making an extensive soft-tissue release unnecessary and the surgery correspondingly easier [14].

The main disadvantages of the iliofemoral distraction technique are the need for the iliofemoral external fixator to be in place for ~3 weeks and the potential for infection at the site of the THA because of the fixation pins; to overcome this problem, we used more fixation pins in the ilium and in the distal femur, which is away from the surgical field for the THA, and we used hydroxyapatite pins. Meticulous pin-site care is mandatory, and the pins are checked daily for stability. Any loose pins are removed immediately. Local pin-site cleaning and application of antibiotics further decrease the chances of infection [31,32]. In our experience, a stable, clean pin track does not usually become infected in 3 weeks, and there were no hip infections in this series.

Dysplastic hips have a shallow acetabulum with a short anteroposterior diameter, and this limits the size of the cup. To overcome this problem, we medialized the center of the hip (cotyloplasty). To deepen the acetabulum, we used a bone graft from the resected femoral head. The survival of the femoral stems within the short period of follow-up was within the expected figures without any undue loosening. There was no varus migration of a stem, no subsidence of more than 5 mm, and no radiolucent line in

any of the Greun zones. We did not encounter any difficulty in managing the abnormal anatomy of the proximal part of the femur; we relied on the anterior surface of the femur and the transcondylar line for orientation of the femoral anteversion. A femoral stem of size 8 was suitable for all the patients. No prophylactic splitting of the femur was required.

To our knowledge, few studies have been published on the technique of iliofemoral distraction in high congenital dislocations of the hips, followed by cementless THA. The study of Lai *et al.* [15,33] is probably the most comprehensive. Lai *et al.* [33] described a technique for the treatment of CDH over 40 mm with iliofemoral distraction before THA in 2005. The Taiwan group recorded 56 patients with a unilateral Crow type-IV hip dislocation, of whom only 48 patients were treated with iliofemoral distraction. The authors used different types of implants; limb-length discrepancy was only 45 mm (30–55 mm) compared with 55 mm (45–70 mm) in the present study. Furthermore, it is noteworthy that no soft tissue was released before distraction and longitudinal femoral splits were not performed to ease implantation of the stem. This might indicate that the technique proposed by the Taiwan group might be comparable with our results. Nevertheless, the longer distraction period and the increase in the Harris hip score were better in the present study (46.4 points) compared with those of Lai *et al.* [33] (26.6 points). Consequently, we do agree with the findings of Lai *et al.* [33] that stretching of the soft tissue alone makes an extensive soft-tissue release unnecessary. We obtained better results in terms of complications of acetabular loosening, pin-site loosening, nerve palsy, and intraoperative fractures.

On the basis of our results, we believe that it is crucial to place the iliac pins as accurately as possible. The authors furthermore extended the prophylactic treatment with antibiotics until the patient was discharged. Pin loosening and infections could be reduced with the use of this technique [34].

This study shows that a closed technique utilizing an Ilizarov fixator for iliofemoral distraction, followed by cementless THA might be a good alternative compared with shortening osteotomies in one-stage THA for patients with a high congenital hip dislocation over 40 mm. However, subtrochanteric shortening osteotomies are certainly indicated when the patient desires a quick solution and limb-length discrepancy is acceptable. However, after a careful evaluation of the patient's demands and the individual risks, the surgeon has to decide which procedure is most suitable on the basis of his experience.

---

## Acknowledgements

### Conflicts of interest

There are no conflicts of interest.

---

## References

- 1 Charnley J, Feagin JA. Low friction arthroplasty in congenital subluxation of the hip. *Clin Orthop* 1973; 91:98–113.

- 2 Crowe JF, Mani VJ, Ranawat CS. Total hip replacement in congenital dysplasia and dislocation of the hip. *J Bone Joint Surg* 1979; 61A:15–23.
- 3 DeLee JF, Charnley J. Radiological demarcation of cemented sockets in total hip replacement. *Clin Orthop* 1976; 121:20–32.
- 4 Dunn HK, Hess WH. Total hip reconstruction in chronically dislocated hips. *J Bone Joint Surg* 1976; 58A:838–845.
- 5 Gruen TA, McNeice GM, Amstutz HC. 'Modes of failure' of cemented stem-type femoral components: a radiographic analysis of loosening. *Clin Orthop* 1979; 141:17–27.
- 6 Harley DK, Wroblewski BM. Long-term results of low-friction arthroplasty in patients 30 years of age or younger. *Clin Orthop* 1986; 21:43–50.
- 7 Fredin H, Unander-Scharin LE. Total hip replacement in congenital dislocation of the hip. *Acta Orthop* 1980; 51:799–802.
- 8 Hartoflakidis G, Stamos K, Karachalios T. Treatment of high dislocation of the hip in adults with total hip arthroplasty. Operative technique and long-term clinical results. *J Bone Joint Surg Am* 1998; 80:510–517.
- 9 Krisic P, Janovic L, Barara V. Long-term results of combined operative reduction of the hip in older children. *J Pediatr Orthop* 1988; 8:532–534.
- 10 Hartoflakidis G, Stamos K, Karachalios T, Ioannidis TT, Zacharakis N, *et al.* Congenital hip disease in adults. Classification of acetabular deficiencies' and operative treatment with acetabuloplasty combined with total hip arthroplasty. *J Bone Joint Surg Am* 1996; 78:683–692.
- 11 Harris WH, Crothers O, Oh I. Total hip replacement and femoral-head bone-grafting for severe acetabular deficiency in adults. *J Bone Joint Surg Am* 1977; 59:752–759.
- 12 Russotti GM, Harris WH. Proximal placement of the acetabular component in total hip arthroplasty. A long-term follow-up study. *J Bone Joint Surg Am* 1991; 73:587–592.
- 13 Schutzer SF, Harris WH. High placement of porous-coated acetabular components in complex total hip arthroplasty. *J Arthroplasty* 1994; 9: 359–367.
- 14 Masonis JL, Patel JV, Miu A, Bourne RB, McCalden R, Macdonald SJ, Rorabeck CH. Subtrochanteric shortening and derotational osteotomy in primary total hip arthroplasty for patients with severe hip dysplasia: 5-year follow-up. *J Arthroplasty* 2003; 18:68–73.
- 15 Lai KA, Liu J, Liu TK. Use of iliofemoral distraction in reducing high congenital dislocation of the hip before total hip arthroplasty. *J Arthroplasty* 1996; 11:588–593.
- 16 Crowe JF, Mani VJ, Ranawat CS. Total hip replacement in congenital dislocation and dysplasia of the hip. *J Bone Joint Surg Am* 1979; 61:15–23.
- 17 Rady AE, Sayed MN, Abdel Aal EHM. Modified lateral approach of the hip. European Hip Society domestic meeting; 23-26 June 2004; Innsbruck, Austria: European Hip Society; 2004.
- 18 Harley DK, Wroblewski BM. Long-term results of low-friction arthroplasty in patients 30 years of age or younger. *Clin Orthop* 1986; 21:43–50.
- 19 Stromberg CN, Herbert PA. Multicenter 10-year follow-up study of cemented revision total hip arthroplasty in patients younger than 55 years old. *J Arthroplasty* 1994; 9:595–601.
- 20 Coventry MB. Selection of patients for total hip arthroplasty. *Instr Course Lect* 1974; 23:136–142.
- 21 Jasty M, Harris WH. Total hip reconstruction using femoral head allografts in patients with acetabular bone loss. *Orthop Clin North Am* 1987; 18:291–299.
- 22 Linde F, Jensen J. Socket loosening in arthroplasty for congenital dislocation of the hip. *Acta Orthop Scand* 1988;591254–591257.
- 23 Eftekhar NS. Variation in technique and specific considerations. In: Eftekhar NS, editor. *Principles of total hip arthroplasty*. St Louis: CV Mosby; 1993. pp. 925–967.
- 24 Fredin H, Unander-Scharin LE. Total hip replacement in congenital dislocation of the hip. *Acta Orthop scand* 1980; 51:799–802.
- 25 Paavilainen T, Hoikka V, Solonen KA. Cementless total hip replacement for severely dysplastic or dislocated hips. *J Bone Joint Surg* 1990; 72B: 205–211.
- 26 Perka C, Fischer U, Taylor WR, Matziolis G. Developmental hip dysplasia treated with total hip arthroplasty with a straight stem and a threaded cup. *J Bone Joint Surg Am* 2004; 86:312–319.
- 27 Anwar MM, Sugano N, Masuhara K, Kadowaki T, Takaoka K, Ono K. Total hip in the neglected congenital dislocation of the hip. *Clin Orthop* 1993; 295:127–134.
- 28 Egli S, Hankemayer S, Muller ME. Nerve palsy after leg lengthening in total replacement arthroplasty for developmental dysplasia of the hip. *J Bone Joint Surg Br* 1999; 81:843–845.
- 29 Hartoflakidis G, Karachalios T. Total hip arthroplasty for congenital hip disease. *J Bone Joint Surg Am* 2004; 86-A:242–250.
- 30 Kerboull M, Hamadouche M, Kerboull L. Total hip arthroplasty for Crowe type IV developmental hip dysplasia: a long-term follow-up study. *J Arthroplasty* 2001; 16:170–176.
- 31 Clasper JC, Stapley SA, Bowley DM, Kenward CE, Taylor V, Watkins PE. Spread of infection, in an animal model, after intramedullary nailing of an infected external fixator pin track. *J Orthop Res* 2001; 19:155–159.
- 32 Lai KA, Lin CJ, Chen JH. Application of locked intramedullary nails in the treatment of complications after distraction osteogenesis. *J Bone Joint Surg Br* 2002; 84:1145–1149.
- 33 Lai KA, Shen WJ, Huang LW, Chen MY. Cementless total hip arthroplasty and limb-length equalization in patients with unilateral Crowe type-IV hip dislocation. *J Bone Joint Surg Am* 2005; 87:339–345.
- 34 Lerch M, Thorey F, von Lewinski G, Klages P, Wirth CJ, Windhagen H. An alternative treatment method to restore limb-length discrepancy in osteoarthritis with high congenital hip dislocation. *Arch Orthop Trauma Surg* 2009; 129:1593–1599.